

An unusual case of metallic foreign body in abdominal cavity: A case report

Slava Bard, Hanoch Kashtan

ABSTRACT

Introduction: The most cases foreign body ingestion has a clear history of swallowing have clear recommendation for treatment. **Case Report:** We want to present an unusual case of an unexpected extra luminal finding of metallic foreign body in abdominal cavity without history of ingestion which was accidentally found by imaging. The metallic foreign body was found on MRCP imaging as usual clearance of bile tract after acute biliary pancreatitis with elevated liver enzymes. The patient denied any history of ingestion any foreign material. This is the first case report of a patient unintentionally transferring outside a foreign body from hollow viscus system without any clinical presentation or reminiscence about it. **Conclusion:** Surgical intervention should be offered to patient if the foreign body causes any symptoms or it can be easily removed during another not related operation.

Keywords: Abdominal cavity, Foreign body, Swallowing of sharp metallic, Sewing needles

How to cite this article

Bard S, Kashtan H. An unusual case of metallic foreign body in abdominal cavity: A case report. J Case Rep Images Surg 2017;3:53–56.

Article ID: 100049Z12SB2017

doi:10.5348/Z12-2017-49-CR-14

INTRODUCTION

Swallowing of sharp metallic foreign bodies is a common in medical practice. It can be a deliberate act or by chance. The first report was mentioned in early 1700s [1]. At that time, not only was dressmaking/tailoring purely manual work leading to the swallowing of sewing needles often held between the lips, but eating of shot game was also still widespread. Today, the overall incidence has dropped to 0.005% [2]. Almost all swallowed foreign bodies pass through gastrointestinal tract in the stool without causing any significant disorders [3]. Sometimes foreign bodies can change their course and penetrate the hollow organ wall, but this is rare and usually quiet [4]. These foreign bodies may move forward to almost any intra-abdominal organ [5]. Often, the identification of a moved foreign body is coincidental when patients appear with unrelated symptoms [6].

We are presenting an unusual case of an unexpected extra luminal finding of metallic foreign body in abdominal cavity without history of ingestion which was accidentally found by imaging. The patient was admitted and managed in our surgical department of Rabin Medical Center, Beilinson Hospital.

Slava Bard¹, Hanoch Kashtan²

Affiliations: ¹MD, Division of General Surgery, Rabin Medical Center, Campus Beilinson, affiliated with Sackler Faculty of Medicine, Tel Aviv University, Israel; ²Professor, Director of General Surgery Division, Rabin Medical Center, Campus Beilinson, affiliated with Sackler Faculty of Medicine, Tel Aviv University, Israel.

Corresponding Author: Slava Bard, Division of General Surgery, Rabin Medical Center, Campus Beilinson, affiliated with Sackler Faculty of Medicine, Tel Aviv University, Israel; Email: slavab@clalit.org.il, bardik1977@gmail.com

Received: 10 June 2017

Accepted: 27 July 2017

Published: 10 August 2017

CASE REPORT

A 42-year-old male usually healthy except episode of mild biliary pancreatitis one month ago attended surgical outpatient clinic. The patient brought the results of imaging MRCP which he electively passed as a step of the preparation for elective surgery— cholecystectomy. He was absolutely asymptomatic last time. The big metallic foreign body in the area of gallbladder was mentioned in the report of MRCP.

The patient denied ingesting of foreign body. His past medical history is clean and excludes deliberate self-harm, taking overdose of medications, bulimia nervosa, anxiety and alcohol excess. He has no past surgical history. The patient also denied swallowing any foreign object in the past. He has no pain or other symptoms referable to this object. On examination, there was no scar visible in the abdominal wall.

Computed tomography (CT) scan of the abdomen was performed to assess the foreign object. Computed tomography scan showed a radio-dense elongated foreign body measuring 20 mm deep to intra-abdomen fat of right upper quadrant in the area of gallbladder lying in its left side (Figure 1).

The patient was asymptomatic related to this foreign body. So, in outpatient clinic was considered to perform elective operation— laparoscopic cholecystectomy with removal of foreign body.

The patient was admitted electively and taken to operation theatre. The patient underwent uneventful laparoscopic cholecystectomy. During the operation the foreign reminiscent of a needle was found stuck in the omentum closed to pylorus (Figure 2–4). He made an uneventful recovery and was discharged home with further follow-up.

DISCUSSION

Ingestion of foreign bodies can occur in adults or children. Case reports of swallowed sharp metallic body perforating the hollow viscus of abdomen, though presenting in literature are surprisingly rare [5]. Complication of foreign body swallowing such as perforation and dislocation of it may be insensitive to the patient [6]. A foreign body can be detected accidentally as part of a patient's radiological examinations for very different reasons. Often, this leads to the surprise of both the doctor and the patient [5]. Sometimes, the foreign body leads to more severe consequences, including perforation, intestinal obstruction, and dislocation of foreign body to almost any sites of abdomen cavity [7].

There was no correlation between the penetration of a foreign body into the gastrointestinal tract and the appearance of symptoms. Note a different period of time, from several months to several years [6].

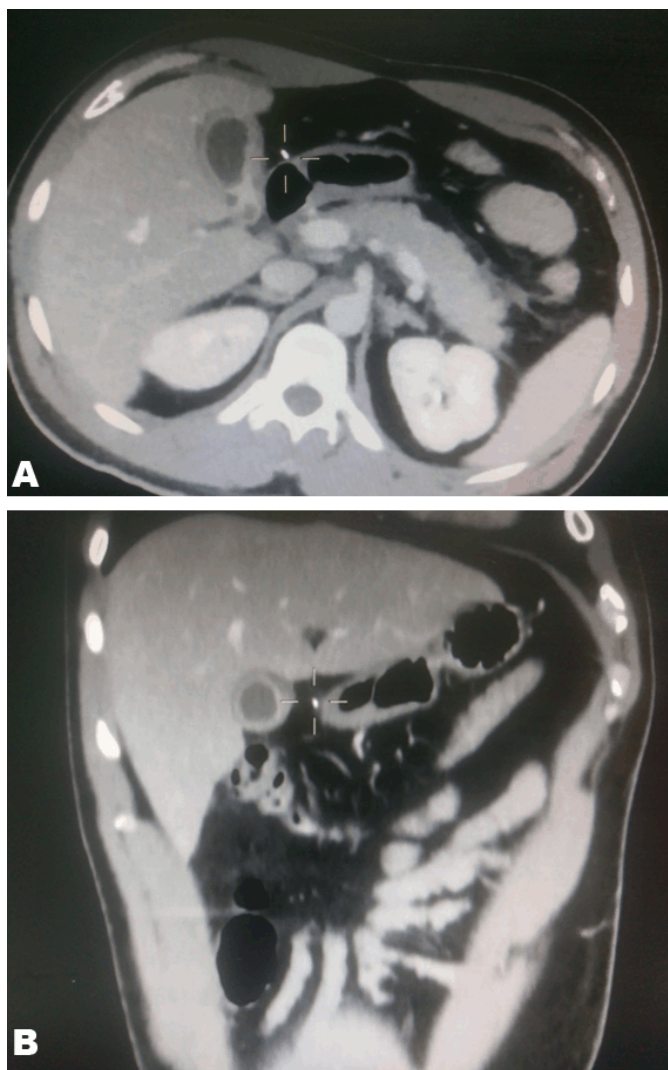


Figure 1: (A, B) Foreign body showing on computed tomography scan.

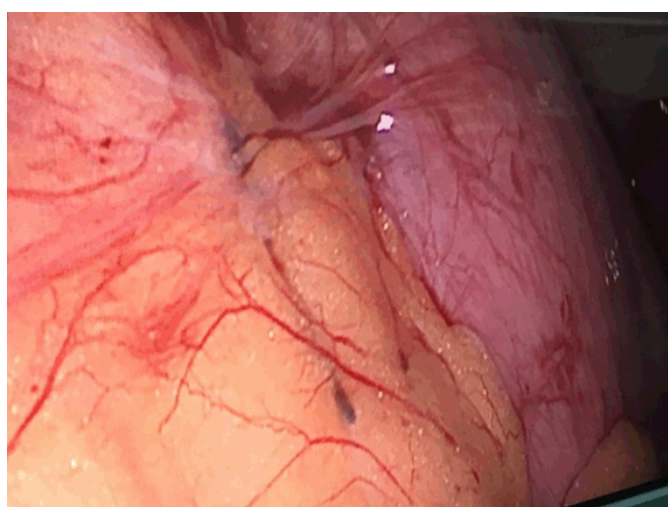


Figure 2: Foreign body in the gastro-colic ligament.

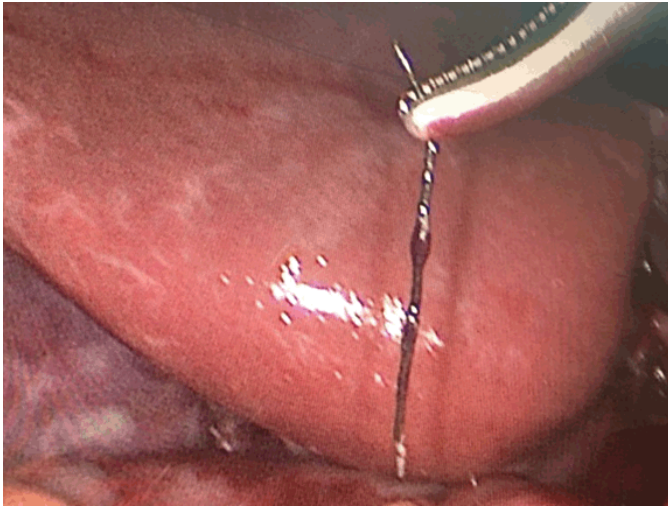


Figure 3: Extracted foreign body handled by endoscopic instrument.



Figure 4: Foreign body in the box, removed from the abdomen cavity.

In our case, the patient was asymptomatic and denied any history of ingesting or inserting a foreign body. The accidental finding of the sharp foreign body in the intra-abdominal fat closed to pylorus on MRCP and CT scan made us a huge surprise, because this finding did not yield to a logical explanation, which in itself made this case unusual and interesting. The possibility could be silent gastrointestinal perforation of foreign body which was swallowed even in his childhood, and its migration to the intra-abdominal fat.

The possibility of penetrating-migrating by a sharp foreign body is widely accepted and the whole process of disease entity is mostly symptom-free and usually an event of time-spending [6].

CONCLUSION

The penetration of foreign bodies into the gastrointestinal tract rarely leads to complications like perforation and is released spontaneously after some time with a fecal mass. Rarely, it may pass quietly to other places of the abdomen. The indication for the surgical intervention exists for patients with obvious symptomatology the cause of which is the foreign body or it can be easily removed during another not related operation.

Author Contributions

Slava Bard – Substantial contributions to conception and design, Acquisition of data, Drafting the article, Final approval of the version to be published

Hanoch Kashtan – Substantial contributions to conception and design, Revising it critically for important intellectual content, Final approval of the version to be published

Guarantor

The corresponding author is the guarantor of submission.

Conflict of Interest

Authors declare no conflict of interest.

Copyright

© 2017 Slava Bard et al. This article is distributed under the terms of Creative Commons Attribution License which permits unrestricted use, distribution and reproduction in any medium provided the original author(s) and original publisher are properly credited. Please see the copyright policy on the journal website for more information.

REFERENCES

1. Klingler PJ, Smith SL, Abendstein BJ, Brenner E, Hinder RA. Management of ingested foreign bodies within the appendix: A case report with review of the literature. *Am J Gastroenterol* 1997 Dec;92(12):2295–8.
2. Balch CM, Silver D. Foreign bodies in the appendix. Report of eight cases and review of the literature. *Arch Surg* 1971 Jan;102(1):14–20.
3. Toyonaga T, Shinohara M, Miyatake E, et al. Penetration of the duodenum by an ingested needle with migration to the pancreas: Report of a case. *Surg Today* 2001;31(1):68–71.
4. Ashby BS, Hunter-Craig ID. Foreign-body perforations of the gut. *Br J Surg* 1967 May;54(5):382–4.
5. Harjai MM, Gill M, Singh Y, Sharma A. Intra-abdominal needles: An enigma (a report of two cases). *Int Surg* 2000 Apr–Jun;85(2):130–2.


6. Chan KW. An unusual case of foreign body in the anterior abdominal wall. *J Clin Med Res* 2010 Mar 20;2(2):93–5.
7. Quantz MA, Brown R. Late presentation of an intra-abdominal foreign body. *Can J Surg* 1997 Aug;40(4):305-7.

ABOUT THE AUTHORS

Article citation: Bard S, Kashtan H. An unusual case of metallic foreign body in abdominal cavity: A case report. *J Case Rep Images Surg* 2017;3:53–56.



Slava Bard is General Surgeon, Foregut Unit at Surgical Division, Beilinson Hospital, Rabin Medical Center, Petach-Tiqwa, Israel). He earned undergraduate degree (MD) from State’s Medical University of Kazakhstan, Almaty, Kazakhstan and postgraduate degree from Surgical Division, Beilinson Hospital, Rabin Medical Center, Petach-Tiqwa, Israel. He has published several research papers in national and international academic journals and authored several books.



Hanoch Kashtan is Professor, Director of General Surgery Division, Rabin Medical Center, Campus Beilinson, affiliated with Sackler Faculty of Medicine, Tel Aviv University, Israel.

Access full text article on
other devices



Access PDF of article on
other devices

